THE FIRST YEAR OUTCOME OF LASER *IN SITU* KERATOMILEUSIS AT THE NARA MEDICAL UNIVERSITY HOSPITAL

YOSHIAKI NAWA, TETSUO UEDA, SHINJI MARUOKA, TOMO NISHI, TAKEO OTA, KOZO MASUDA and YOSHIAKI HARA

Department of Ophthalmology, Nara Medical University School of Medicine

Received April 2, 2007

Abstract : We report the first-year outcome of laser *in situ* keratomileusis (LASIK) at the Nara Medical University Hospital. The follow-up periods ranged from one month to one year. Among 30 eyes of 15 patients who underwent LASIK for myopia or myopic astigmatism, 29 eyes (96.7%) obtained an uncorrected visual acuity of 20/20 or better with subjective refraction of ±0.5D of emmetropia. Complications were undercorrection (one eye) and diffuse lamellar keratitis (one eye). Both eyes underwent reoperation and obtained good vision.

We conclude that the first-year outcome of LASIK at the Nara Medical University Hospital is excellent.

Key words : LASIK, keratorefractive surgery

INTRODUCTION

Laser *in situ* keratomileusis (LASIK) is currently the most prevalent keratorefractive surgery in the world[1]. In Japan, it is estimated that more than eighty thousand cases are operated annually (NIDEK excimer meeting, Hakone, Nov. 2006).

LASIK was first invested by Pallikaris in 1990 as a combination of previously used techniques[2]. It involves the use of a microkeratome to create a thin flap, followed by excimer laser ablation of the cornea. Corneal lamellar surgery was first described by Barraquer in 1949[3]. It was later modified as an automated lamellar keratoplasty[4]. Excimer laser was first performed as photorefractive keratectomy (PRK) in 1983[5]. Marked advances of excimer laser technology and development of safer microkeratomes have led to the rapid spread of LASIK. The surgical procedure of LASIK is depicted in Fig.1.

In the Nara Medical University Hospital, excimer laser equipment was installed in Dec. 2005.

After meticulous preparations, we inifiated LASIK procedures in Jan. 2006. As of Jan. 2007, we report the first-year outcome of LASIK at the Nara Medical University Hospital.

MATERIAL AND METHODS

Thirty-two eyes of 17 patients who underwent LASIK at the Nara Medical University Hospital in 2006 were enrolled for the analysis. The age of patients ranged 21 to 64 years old (30±8). Two eyes of 2 patients (40 and 64 y.o.) were hyperopia. Thirty eyes of 15 patients were myopia or myopic astigmatism. Follow-up periods ranged from 1 month to 1 year.

LASIK was performed in a standard fashion. Two surgeons (Y.N. and T.U.) operated alternately. Briefly, a topical anesthesia was administered with commercially available 4% lidocaine hydrochloride (4% Xylocaine®, Astrazeneka, Tokyo, Japan). The eyelid was sterilized with povidone-iodine (Isodine®, Meiji, Tokyo, Japan) and draped. A 130 or 160 micron depth, 8.5mm to 9.5mm diameter corneal flap was created with the microkeratome (MK-2000, NIDEK, Gamagori, Japan). Ablation of the corneal stroma was performed with the excimer laser (EC-5000 CXⅡ, NIDEK). After washing the surface of the corneal stroma with saline, the flap was repositioned by spatula. Steroids (Methylprednisolone, Solu-medrol 40®, Pfizer, Tokyo, Japan) and antibiotics (Gentamicin sulfate, Gentacin®, Shering Plough, Osaka, Japan) were added to the saline (40mg Solu-medrol and 60mg gentamicin in 100ml saline) from the sixth case. The corneal flap was dried for reattachment for three minutes. Commercially available antibiotics, steroid, and hyalulonic acid eyedrops (0.5% levofloxacin, Curavit®, Santen, Osaka ; 0.1% fluometholone, 0.1% Fluometholone®, Nihon Tenganyaku, Nagoya; 0.1% sodium hyaluronate, Hyalein®, Santen, Osaka) were prescribed and continued for one to six months, depending on the eye condition.

Pre-and postoperative uncorrected visual acuity, spherical equivalent of subjective refraction, absolute amount of astigmatism, and postoperative complications were evaluated.

RESULTS

Overall, two eyes of two patients had a re-operation. One eye of one myopic patient underwent re-operation at six months due to an undercorrection of myopia. One eye of one patient developed severe diffuse lamellar keratitis and underwent flap lifting and washing of

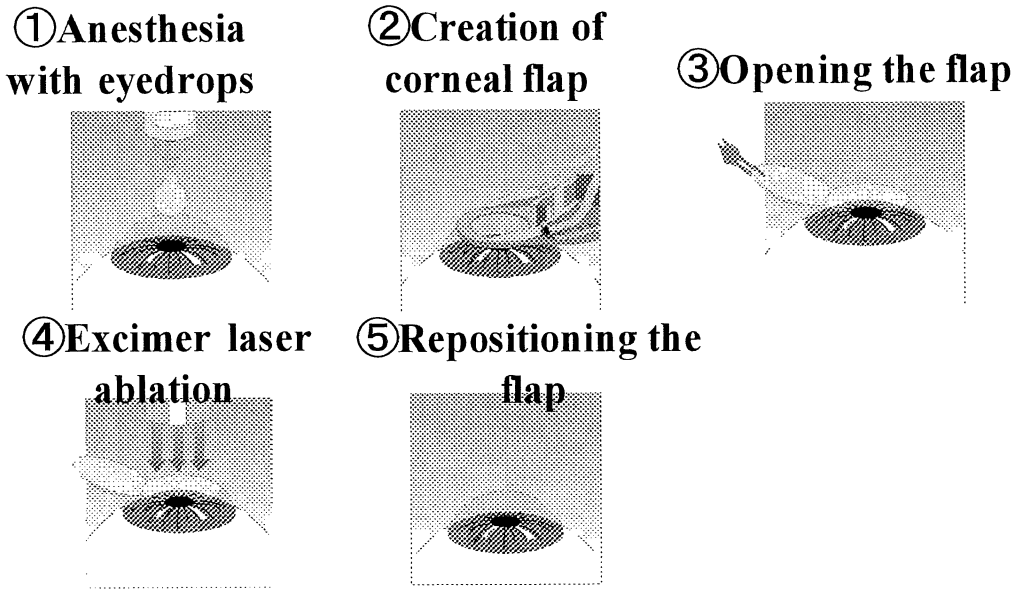

Fig.1. The surgical procedure of LASIK.

the interface with saline containing steroid and antibiotics as described in the Methods section.

Visual acuity

In eyes with myopia or myopic astigmatism, 29 eyes (96.7%) obtained uncorrected visual acuity of 20/20 or better at the final visit of the initial surgery. Thirty eyes (100%) obtained uncorrected visual acuity of 20/20 or better at the final visit of the second surgery (Fig.1).

In two eyes with hyperopia, preoperative uncorrected visual acuities of 20/50 and 20/200 improved to 20/22 and 20/25, respectively.

Subjective refraction

In eyes with myopia or myopic astigmatism, 29 eyes (96.7%) obtained ±0.50D of emmetropia at the final visit of the initial surgery. Thirty eyes (100%) obtained ±0.50D of emmetropia at the final visit of the second surgery (Fig. 2).

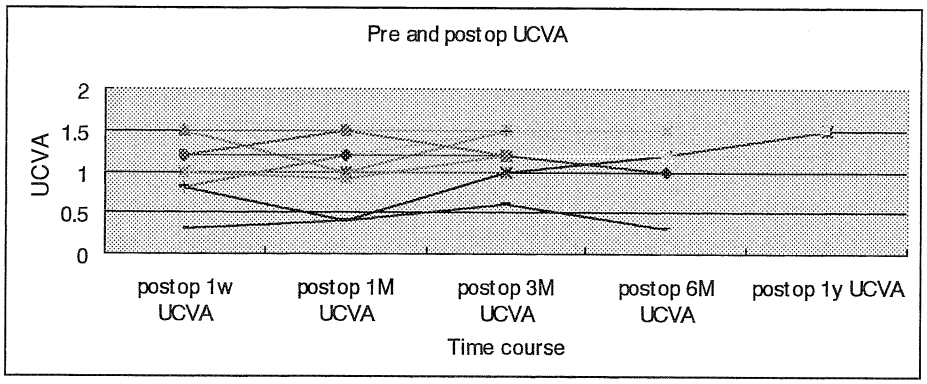

Fig. 2. Time course of pre-and postoperative uncorrected visual acuity (UCVA) of 30 eyes with myopia or myopic astigmatism. The eye with an uncorrected visual acuity of 20/50 at six months after surgery obtained 20/20 at one week after re-operation.

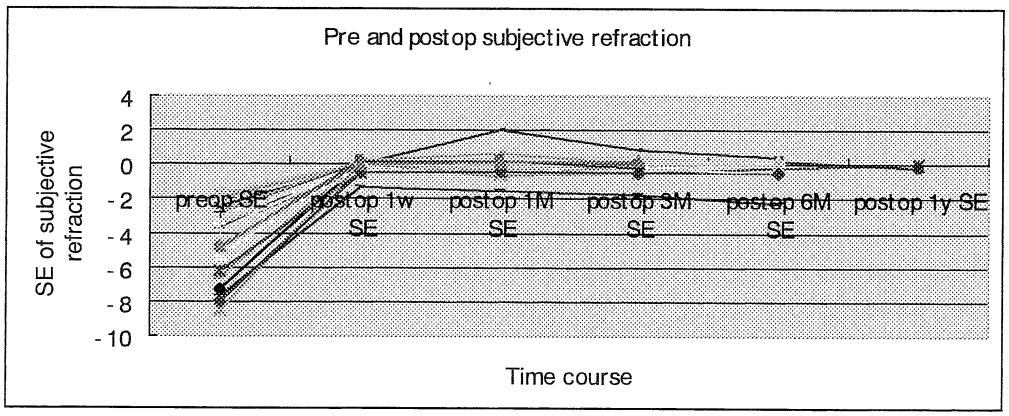

Fig. 3. Time course of pre and postoperative spherical equivalent (SE) of subjective refraction (Diopters) of 30 eyes with myopia or myopic astigmatism. One eye with diffuse lamellar keratitis showed temporal hyperopic shift up to 2 diopters at one month, which gradually improved toward emmetropia over the next five months. One undercorrected eye was re-operated immediately after the point of six months.

In two eyes with hyperopia, preoperative refraction of +2.00 and +2.00 improved to −0.50 and −0.13D, respectively.

Absolute amount of astigmatism

In eyes with myopia or myopic astigmatism, the amount of preoperative astigmatism ranged from 0 to 1.75D (0.51 ±0.53). Postoperatively, the amount of astigmatism significantly decreased, ranging from 0 to 2.00 (0.27 ±0.43) (P=0.036, paired t-test).

In eyes with hyperopia, the preoperative amount of astigmatism of 0 and 1D increased to 1.25 and 1.75D, postoperatively.

Complications

In one eye of one patient, diffuse lamellar keratitis was noted at the second day of the initial surgery. Despite topical steroid eyedrops and oral predonisolone, the keratitis progressed. At the fifth day of the initial surgery, the patient underwent washing of the corneal flap interface with saline containing steroid and antibiotics as described in the Methods section. The keratitis gradually subsided over one month. The uncorrected visual acuity was 20/60 with subjective refraction of +2.00 at one month after the initial surgery. These improved to 20/20 and +0.88 at three months and 20/12 and +0.50 at six months.

In one eye of one patient uncorrected visual acuity and subject refraction remained 20/50 and −2.25 at six months after the initial surgery. The patient underwent re-operation to enhance the correction. The corneal flap of the initial surgery was lifted by spatula. Excimer laser ablation based on the topography-linked system was performed. The corneal surface was washed and the corneal flap was repositioned. A bandage soft contact lens was placed. The postoperative course was excellent. The bandage contact lens was removed at the fifth day after the surgery. The eye obtained an uncorrected visual acuity of 20/20 with subjective refraction of −0.38D at one week after the surgery.

DISCUSSION

Our one-year outcome of LASIK was excellent despite being affected by the learning curve of the surgical skills, gradual improvement of the setting of the surgery, operating room, and methods of sterilization of the surgical instruments.

The percentage of uncorrected visual acuity of better than 20/20 and subject refraction of ±0.5D after the initial surgery were 96.7%. This result is excellent, compared with the most recent reports in Japan (±0.5D: 81.6%[6], 77.4%[7], 83.0%[8], 88.0%[9]) and English-language literature (±0.5D : 87.0%[10], 71.0%[11], 92.0%[12], 95.0%[13]).

Probable reasons for the good predictability are our traditional meticulous technique of measuring subjective refraction (the second method of evaluating subjective refraction[14]), good condition of the operating room (No.12 room in the C building, in which temperature and humidity are constantly maintained), and good surgical skills.

The percentage of diffuse lamellar keratitis has been reported to occur at a percentage of 1 to 12[15]. The incidence in our series was 3.3%, within the range of the incidences of the past reports. Possible causes are microkeratome oil, debris, Meibomian gland secretions, and bacterial endotoxins[15]. Although in most cases the inflammation and visual blur is reversible,

sometimes it takes several months for the visual function to recover as observed in our case. We will still have to be careful in the pre- and postoperative patient care.

CONCLUSION

In conclusion, our first-year result of LASIK was excellent. We will have to make maximal efforts to maintain the predictability of the surgery, while concurrently increasing the number of procedures conducted.

REFERENCES

1) **Shortt, A.J., Bunce, C.** and **Allan, B.D.**: Evidence for superior efficacy and safety of LASIK over photorefractive keratectomy for correction of myopia. Ophthalmology **113** : 1897-1908, 2006.
2) **Pallikaris, I.G., Papatzanaki, M.E., Stathi, E.Z., Frenschock, O.** and **Georgiadis, A.**: Laser in situ keratomileusis. Lasers Surg. Med. **10** : 463-468, 1990.
3) **Barraquer, J.**: Oueratoplastia refractiva. Estudio Inform. Oftal. Inst. Barraquer. **10** : 2-21, 1949.
4) **Krumeich, J.H.**: Keratomileusis. A new surgical technic in eye surgery. Information for the general practitioner. Z.F.A.(Stuttgart). **57** :1321-1326, 1981.
5) **Marshall. J., Trokel, S., Rothery, S.** and **Schubert, H.**: An ultrastructural study of corneal incisions induced by an excimer laser at 193 nm. Ophthalmology **92** :749-758, 1985.
6) **Hori-Komai, Y., Sakai, S., Ito, M., Yamamoto, T., Nakajima, K.,** and **Toda, I.**: Clinical outcome of Laser in situ keratomileusis using excimer laser CZM80 and microkeratome MR2. Atarashii Ganka **22** : 1685-1689, 2005.
7) **Aizawa, D., Shimizu, K., Nakanishi, M., Suzuki, M., Ohno, A.,** and **Komatsu, M.**: Two-year result of laser in situ keratomileusis. Nippon Ganka Gakkai Zasshi **109** : 88-92, 2005.
8) **Yokokawa, H., Ueyama, M., Nitta, K., Ogino, Y., Saito, Y., Kobayashi, K.,** and **Sugiiwama, K.**: Early result of Laser in situ keratomileusis (LASIK) at Fukui Saiseikai Hospital. Folia Jpn. Ophthalmol. **55** : 291-296, 2004.
9) **Yorii, H., Yorii, M., Nishitani, M.,** and **Takagi M.**: Result of myopic correction surgery. Rinsho Imabari **14** : 8-10, 2002.
10) **Kermani, O., Schmiedt, K., Oberheide, U.,** and **Gerten, G.**: Topographic- and wavefront-guided customized ablations with the NIDEK-EC5000CXII in LASIK for myopia. J. Refract. Surg. **22** : 754-763, 2006.
11) **Tobaigy, F.M., Ghanem, R.C., Sayegh, R.R., Hallak, J.A.** and **Azar, D.T.**: A control-matched comparison of laser epithelial keratomileusis and laser in situ keratomileusis for low to moderate myopia. Am. J. Ophthalmol. **142** : 901-908, 2006.
12) **Montes-Mico, R., Rodriguez-Galietero A.,** and **Alio J.L.**: Femtosecond laser versus mechanical keratome LASIK for myopia. Ophthalmology **114** : 62-68, 2007.
13) **Venter, J.**: Wavefront-guided LASIK with the NIDEK NAVEX platform for the correction of myopia and myopic astigmatism with 6-month follow-up. J. Refract. Surg. 21: 640-645, 2005.
14) **Kawao, M., Nawa, Y., Ueda, T., Yoshimoto, H., Nakagawa, A., Matsuda, T., Masuda, N.** and **Hara, Y.**: Comparison of the first and second method of measuring subjective refraction. Jpn. J. Vis. Sci.. **25** : 66-70, 2004.
15) **Johnson, J.D., Harissi-Dagher, M., Pineda, R., Yoo, S.** and **Azar, D.T.**: Diffuselamellar keratitis: Incidence, associations, outcomes, and a new classification system. J. Cataract Refract. Surg. **27** : 1560-1566, 2001.