

FOLLICULAR GROWTH BY HUMAN MENOPAUSAL GONADOTROPIN STIMULATION IN ECTOPIC PREGNANCY : A CASE REPORT

HIRATSUGU HASHIMOTO

Hashimoto Ladies' Clinic

YOSHIYA ANDO

Department of Obstetrics and Gynecology, Wakayama Medical University, Kihoku Hospital

YOSHINARI MATSUMOTO

Department of Obstetrics and Gynecology, Osaka City University, Medical School

Received March 8, 2004

Abstract : A 29-year-old woman from our in-vitro fertilization (IVF) program was diagnosed with a ruptured ectopic pregnancy. From the crown-rump length of the fetus being 10 mm, we assessed her as being pregnant from her former spontaneous menstrual cycle. An emergency operation was performed and her postoperative condition was good.

Key words : In-vitro fertilization, embryo transfer, ectopic pregnancy

INTRODUCTION

There have been no reports of follicular growth by human menopausal gonadotropin (HMG) in pregnancy. Naturally, follicular growth and ovulation are suppressed in the pregnant state. We report that HMG administration affected follicular growth in an early phase of an ectopic pregnancy.

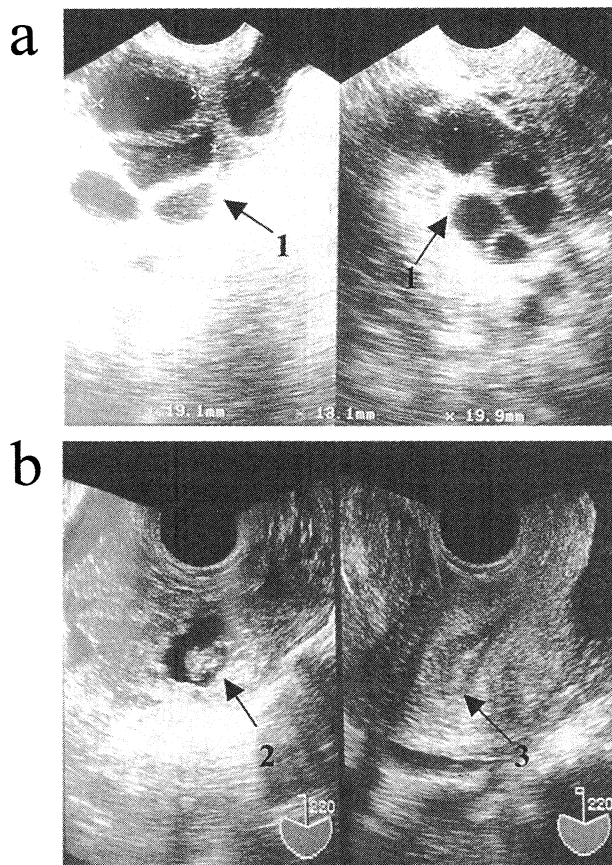
CASE REPORT

A 29-year-old woman, gravida 0, para 0, with a regular menstrual cycle, had experienced 4 years of infertility. Tubal stenosis was confirmed by hysterosalpingography and she was scheduled for a first IVF program in March 2000, after informed consent was obtained. Her next menstrual bleeding started from 22 April.

She visited our clinic on 26 May for her second scheduled IVF with a short protocol of gonadotropin-releasing hormone agonist. She said her last menstrual period started from 25 May but she had not kept an accurate record of her basal body temperature (BBT) from April. We did not test her human chorionic gonadotropin level, ascertained from urine (U-hCG), at the time.

She had undergone ovarian stimulation. Transvaginal echo showed 2 follicles with diameters over 19mm at cyclic day 11, and 2 eggs were retrieved on cyclic day (CD) 12 (Figure a). On CD15, a two-embryo transfer was performed.

She complained of lower right abdominal pain on CD26, and transvaginal echo revealed a collection of ascites, and a fetal heart beat in the right adnexa (Figure b). Crown-rump length of the fetus was 10mm, equivalent to 7 weeks 2 days gestation. Her U-hCG was over



- ← 1 : Bi-lateral enlarged follicle by HMG stimulation
- ← 2 : Ectopic pregnant fetus
- ← 3 : No gestational sac in uterine cavity

Figure. (a), Trans vaginal ultrasonic echo one day before follicular puncture (cyclic day 11), (b), Trans vaginal ultrasonic echo cyclic day 26 when the ectopic pregnancy was diagnosed. CRL was 10 mm and fetal heartbeat was confirmed in right adnexa.

50 IU/l. We diagnosed a ruptured ectopic pregnancy, and assessed that she became pregnant in the former spontaneous menstrual cycle.

After informed consent was obtained, an emergency operation was performed. A transfusion was needed for hypovolemic shock caused by more than 1200 ml of blood in the abdominal cavity. Right salpingectomy and partial ovarian resection was done. Chorionic villi and a fetus were identified in the operative specimen after pathological examination.

Postoperative day 19, her U-hCG was under 50 IU/l and her condition was good.

DISCUSSION

Ectopic pregnancy is much more frequent after IVF^{1,2)}. In this case, in view of the spontaneous pregnancy, we should have checked her BBT and U-hCG more carefully. But the gestational sac and the fetal heart beat of the ectopic fetus were not identified outside the uterine cavity at the times of her egg retrieval and embryo transfer by using ultrasonography.

Folliculogenesis refers to the continuous process that occurs throughout reproductive life whereby cohorts of primordial follicles undergo maturation during each menstrual cycle. Follicular maturation begins during the luteal phase and is continuous throughout the follicular phase of the next cycle. Each month only one such follicle, the periovulatory or dominant follicle, achieves complete maturation. The other follicles undergo atresia at earlier stages of their development. Folliculogenesis and atresia continue during pregnancy, although they do not reach the periovulatory follicle stage³⁾.

In this case, two eggs were retrieved. Both were fertilized, and grew to 4 cells but were not nidated. Maturation of follicles can be induced by ovarian stimulation for ovulation induction with exogenous follicle stimulation hormone and HCG during early pregnancy. Despite our mistakes, this case brought us a new stock of knowledge, and from this we have learned, thus ensuring that our service could be provided with more informed care.

REFERENCES

- 1) Rizk, B., Tan, S.L., Morcos, S., Riddle, A., Brinsden, P., Mason, B.A. and Edwards, R.G. : Heterotopic pregnancies after in vitro fertilization and embryo transfer. *Am. J. Obstet. Gynecol.* **164** : 161-164, 1991.
- 2) Lower, A.M. and Tyack, A.J. : Heterotopic pregnancy following in-vitro fertilization and embryo transfer. Two case reports and a review of the literature. *Hum. Reprod.* **4** : 726-728, 1989.
- 3) Philip, B.C. : *Anatomy and Histology of the ovary.* Robert, J.K., Blaustein's Pathology of the female genital tract, 4th ed. New York: Springer-Verlag, New York, inc., 568, 1994.