

THICKENING AND MULTILAMELLAR APPEARANCE OF THE ANTERIOR LENS CAPSULE AND RELATED FACTORS

KAZUO TSUTSUI, YOSHIAKI NAWA, SACHIKO UEMURA, MITSUO TSUKAMOTO,
TOSHIO SHIMIZU, MASAYA KOMINAMI and YOSHIAKI HARA

Department of Ophthalmology, Nara Medical University

Received November 19, 2003

Abstract : The purpose of this study was to investigate which factors (including age, sex, grade of cataract, diabetes mellitus (DM), pseudoexfoliation, glaucoma, and atopy) are correlated with thickening and/or multilamellar appearance of the anterior lens capsule.

Seventy-two anterior lens capsules were obtained during cataract surgeries. They were fixed, embedded in paraffin, and stained with Periodic acid-Schiff (PAS) and Masson-Trichrome. We measured thickness of the anterior capsules on microscopic photographs. In addition, multilamellar appearance of the anterior capsules was graded by an experienced ophthalmic pathologist and scored (0~3.0). By multiple regression analysis we evaluated whether the seven factors described above were correlated with thickness and/or multilamellar appearance of the anterior capsules.

Thickness of the anterior capsule was correlated with DM and age ($p=0.0095$ and $p=0.0138$, respectively). Multilamellar score was significantly correlated with age ($p<0.0001$). Both had no significant relationships with other factors.

This is the first report that showed the above mentioned relationships with multiple regression analysis.

Key words : anterior lens capsule, multilamellar appearance, cataract surgery

INTRODUCTION

The lens capsule has been recognized as a specialized type of collagen since the 1950's. Now classified as a typical basement membrane secreted by, and tightly attached to, the epithelium, the lens capsule acts as an important permeability barrier for substances entering and leaving the lens¹⁾.

In the era of small-incision cataract surgery, phakic IOLs, and direct lens refilling (possibly in the near future), we have to better understand the property of the anterior lens capsule.

However, we have been unable to find reports that investigated whether thickness and/or multilamellar structure of the anterior capsule were correlated with age, sex, grade of cataract, diabetes mellitus (DM), pseudoexfoliation, glaucoma, and atopy, by multiple regression analysis. We conducted such a study and present the results in this paper.

MATERIALS AND METHODS

Seventy-two anterior lens capsules were obtained during 72 consecutive small-incision cataract surgeries performed at the Department of Ophthalmology, Nara Medical University in 2002. The mean (\pm standard deviation (SD)) age of the patients was 68 ± 16 (range 21 to 92) years. Age, sex, nucleus grade of cataract (Emery-Little classification), DM, pseudoexfoliation, glaucoma, and atopy were recorded.

After continuous curvilinear capsulorhexis (CCC), the anterior lens capsules were removed through the superior corneoscleral tunnel and immediately fixed in 10% formalin. After several hours of fixation at room temperature, they were embedded in paraffin; $6\mu\text{m}$ -thick sections were stained with Periodic acid-Schiff (PAS) and Masson-Trichrome.

In all cases a monolayer of lens epithelial cells with an adjacent lens capsule were present on microscopic slides. In each case photographs were taken at a magnification of $\times 400$.

Thickness of the anterior lens capsules was measured at more than ten different portions of each photograph and averaged. The measurement was conducted in a masked fashion.

Multilamellar appearance of the anterior capsule was examined on microscopic slides by one experienced eye pathologist. In both stains, the multilamellar appearance of the anterior capsule was classified into three grades (none: $-$, mildly observed: $+$, clearly observed: $++$). These grades were converted to three kinds of values for statistical analysis (multilamellar score ($-$: 0, $+$: 0.5, $++$: 1.0)). If intralamellar separation of the lens capsule was present, it was scored as 1.0 and added to the multilamellar score. During examination the pathologist did not know in which category each slide belonged.

Multiple regression analysis was performed to evaluate whether the thickness and/or multilamellar score had correlations with the seven factors described above.

RESULTS

Figs. 1 to 6 show examples of the grades of multilamellar appearance of the anterior capsules. Fig. 7 shows a case of intralamellar separation of the anterior capsule. Fig. 8 shows an area of subepithelial fibrosis in a case of atopy.

The mean (\pm SD) age of the patients was 68 ± 16 (range 21 to 92) years. In 72 cases, the number of females was 40 (56%). The numbers of the clinical diagnoses were as follows: normal 38 (53%), DM 24 (33%), pseudoexfoliation 6 (8%), glaucoma 4 (6%) and atopy 3 (4%). The mean (\pm SD) nucleus grade of cataract was 2.27 ± 0.72 . The mean (\pm SD) thickness and multilamellar score was 16.2 ± 4.7 (range 6.9 ~ 33.3) μm and 1.11 ± 0.81 (range 0 ~ 3), respectively. Multiple regression analysis revealed that thickness of the anterior capsule was correlated with DM and age ($p=0.0095$ and $p=0.0138$, respectively), and that multilamellar score was significantly correlated with age ($p<0.0001$). Thickness and multilamellar score had no relationships with sex, nucleus grade of cataract, pseudoexfoliation, glaucoma, and atopy.

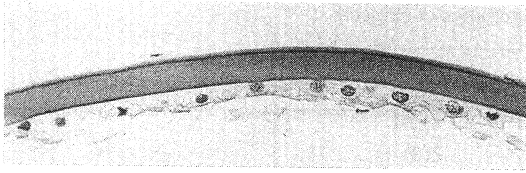


Fig. 1. A case of PAS(-). (×400) 72years, female




Fig. 2. A case of PAS(+). (×400) 78years, female




Fig. 3. A case of PAS(++). (×400) 86years, female

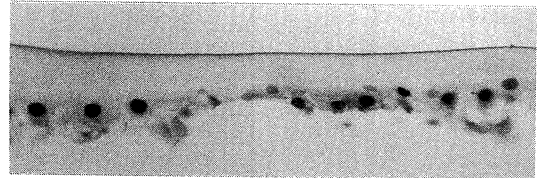


Fig. 4. A case of Masson-Trichrome(-). (×400) 24years, male

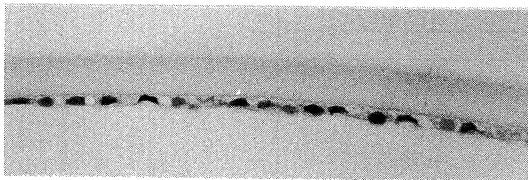


Fig. 5. A case of Masson-Trichrome(+). (×400) 75years, female

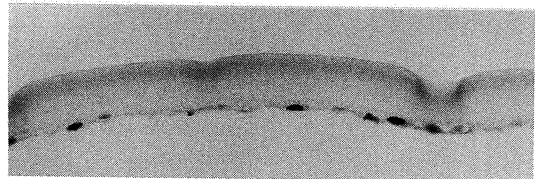


Fig. 6. A case of Masson-Trichrome(++). (×400) 86years, female

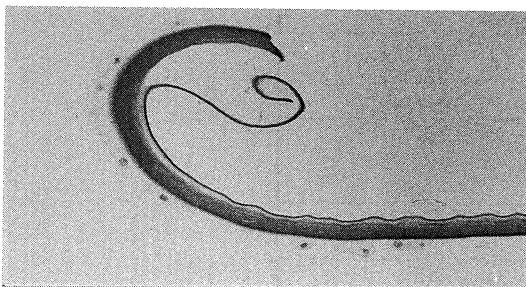


Fig. 7. Intralamellar separation of the anterior capsule. (×200) 86years, male

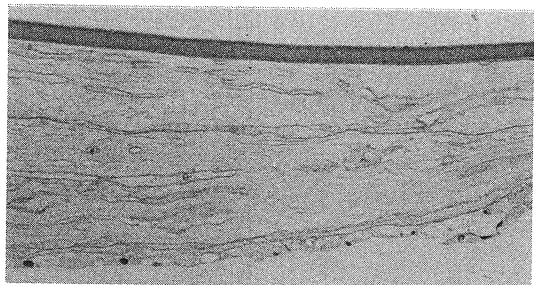


Fig. 8. An area of subepithelial fibrosis in a case of atopy. (×200) 30years, male

Table 1. Baseline characteristics of subjects

Baseline characteristics	Total number=72
1) Age	n(%)
0~29	4(6)
30~39	2(3)
40~49	2(3)
50~59	5(7)
60~69	18(25)
70~79	31(43)
80~89	8(11)
90~99	2(3)
mean (\pm SD), years	67.9(\pm 15.8)
min	21
max	92
2) Female sex, number(%)	40(56)
3) Nucleus grade(Emery-Little), number(%)	
≥ 0 to 1 >	1(1)
1 to 2 >	7(10)
2 to 3 >	43(60)
3 to 4 >	17(24)
4 <	4(6)
mean (\pm SD)	2.27 \pm 0.72
4) Clinical diagnosis, number(%)	
normal	38(53)
diabetes mellitus	24(33)
pseudoexfoliation	6(8)
glaucoma	4(6)
atopy	3(4)
5) Thickness of anterior capsule (μ m)	
mean (\pm SD)	16.2 \pm 4.7
min	6.9
max	33.3
6) Histological changes, number(%)	
PAS(-) score 0	32(44)
PAS(+) score 0.5	26(36)
PAS(++) score 1.0	14(19)
MT(-) score 0	18(25)
MT(+) score 0.5	12(17)
MT(++) score 1.0	42(58)
separation(-) score 0	67(93)
separation(+) score 1.0	5(7)
fibrosis	2(3)
7) Multilamellar score, number(%) (PAS+MT+separation)	
0	14(19)
>0 to >1	8(11)
1 to 2 >	36(50)
2 to 3 >	10(14)
3	4(6)
mean (\pm SD)	1.11 \pm 0.81

Table 2. Relationships between thickness of the anterior lens capsule and seven factors (multiple regression analysis)

Factor	Regression Coefficient	Standard Error	Standard Regression Coefficient	t Value	p Value
age	0.118	0.047	0.394	2.533	0.0138
sex	-0.116	1.137	-0.012	-0.102	0.9187
DM	3.187	1.191	0.319	2.675	0.0095
pseudoexfoliation	-0.545	1.947	-0.032	-0.280	0.7804
glaucoma	-1.410	2.374	-0.069	-0.594	0.5546
atopy	0.392	3.401	0.017	0.115	0.9086
grade of cataract	-0.086	0.860	-0.013	-0.100	0.9206

Table 3. Relationships between multilamellar score and seven factors (multiple regression analysis)

Factor	Regression Coefficient	Standard Error	Standard Regression Coefficient	t Value	p Value
age	0.034	0.007	0.681	5.245	<0.0001
sex	-0.071	0.160	-0.045	-0.446	0.6571
DM	-0.224	0.168	-0.133	-1.336	0.1862
pseudoexfoliation	0.383	0.274	0.133	1.396	0.1675
glaucoma	0.273	0.334	0.079	0.817	0.4169
atopy	0.616	0.479	0.155	1.288	0.2023
grade of cataract	-0.119	0.121	-0.106	-0.981	0.3305

DISCUSSION

Many kinds of the basement membranes of the body continue to thicken during life²⁻⁴. On light microscopic slides of eyes of elderly patients we frequently observe thickened anterior lens capsules⁵. Our study well corresponds to them. Our study also shows that as human becomes older the multilamellar structure of the capsule becomes more evident. A similar basement membrane of the ocular tissue, Descemet's membrane, also shows marked age-related thickening and multilamellarity⁶.

This thickening of the anterior lens capsule may hamper exchanges of materials between the lens epithelial cells and the anterior chamber. This may be a factor of age-related decrease of function, including cataract and presbyopia.

DM also contributes to thickening of the basement membranes of various organs⁷⁻⁹. Therefore it is reasonable that the anterior capsule, that is the basement membrane of the epithelial cells, becomes thickened in diabetic patients. This thickening may be related to fluctuation of refraction and early onset of cataract in diabetic patients.

Why did the multilamellar score differ between the two staining methods in some cases? PAS stain is one of the most widely used methods in light microscopic study in the field of ocular pathology¹⁰. It reacts intensely with basement membrane of the tissue. We can clearly observe the thickening of the basement membrane of various eye components at a glance. However, sometimes PAS stains become too intense to detect small differences of components.

Masson-Trichrome stain reacts with collagen¹⁰. The main component of the anterior lens capsule is the collagenIV^{1,5}. Collagen I, III, and V have also been detected^{11,12}. Other components include proteoglycan heparan sulfate, and glycoprotein adhesion protein laminin

combined with a polysaccharide⁹). In our impression, scores graded with Masson-Trichrome stain may have reflected more precisely the actual multilamellarity of the anterior lens capsule.

Continuous curvilinear capsulorhexis (CCC) is widely performed during cataract surgery. Occasionally CCC results in a double-contour appearance, especially in elderly patients. This phenomenon suggests that an intralamellar zone of the anterior lens capsule, that is mechanically weak and easily separated, may emerge in elderly patients. The increase of multilamellar appearance of the anterior lens capsule in elderly patients may be related to the above mentioned phenomenon. Wollensak et al reported similar changes in the semithin sections ($0.6\mu\text{m}$) and on electron microscopy¹³).

Similar capsular separation is also observed in true exfoliation⁵). True exfoliation is rarely seen in elderly persons. The area of separation is variably located in true exfoliation^{5, 14, 15}). It is plausible that multilamellar capsules in elderly persons are prone to cause splits and subsequent large intralamellar separation.

CONCLUSION

Multiple regression analysis revealed that thickness of the anterior lens capsule was correlated with DM and age. Multilamellar score was significantly correlated with age. These relationships may be related to various eye diseases.

REFERENCES

- 1) **Berman, E. R.** : Biochemistry of the Eye. Plenum Pub. Corp, New York, p.217, 1991.
- 2) **Richardson, L. L., Kleinman, H. K. and Dym, M.** : The effect of aging on basement membrane in the testis. *J. Androl.* **16** : 118-126, 1995.
- 3) **Vazquez, F., Palacios, S., Aleman, N. and Guerrero, F.** : Changes of the basement membrane and type IV collagen in human skin during aging. *Maturitas.* **25** : 209-215, 1996.
- 4) **Thomopoulos, G. N., Spicer, S. S., Gratton, M. A. and Schulte, B. A.** : Age-related thickening of basement membrane in stria vasularis capillaries. *Hear. Res.* **111** : 31-41, 1997.
- 5) **Eagle, R. C. and Spencer, WH.** : Lens. In : *Ophthalmic Pathology.* Vol 1, W.B.Saunders Company, Philadelphia, pp.372-398, 1996.
- 6) **Johnson, D. H., Bourne, W. M. and Compbell, R. J.** : The ultrastructure of Descemet's membrane. I. Changes with age in normal corneas. *Arch. Ophthalmol.* **100** : 1942-1947, 1982.
- 7) **Brito, P. L., Fioretto, P., Drummond, K., Kim, Y., et al.** : Proximal tubular basement membrane with insulin-dependent diabetes mellitus. *Kidney Int.* **53** : 754-761, 1998.
- 8) **Younes, B., Baez-Giangreco, A., al-Nuaim, L., al-Hakeem, A. and Abu Talib, Z.** : Basement membrane thickening in the placenta from diabetic women. *Pathol. Int.* **46** : 100-104, 1996.
- 9) **Hill, R. E. and Williams, R. E.** : A quantitative analysis of perineurial cell basement membrane collagen IV, laminin and fibronectin in diabetic and non-diabetic human sural nerve. *J. Anat.* **201** : 185-192, 2002.
- 10) **Apple, D. J. and Naumann, GOH.** : General anatomy and development of the eye. Techniques of investigation. In : *Pathology of the Eye.* Springer-Verlag, New York, pp.13-16, 1985.
- 11) **Kawarazaki, Y.** : Histochemical study of human lens capsule-immunohistochemical analysis of collagen. *Nippon Ganka Gakkai Zassi* **100** : 284-291, 1996.
- 12) **Majo, F., Montard, M., Delbosc, B. and Kantelip, B.** : Immunolabelling of collagen types I, III, IV,

laminin, and fibronectin in the human lens capsule. *J. Fr. Ophthalmol.* **20** : 664-670, 1997.

- 13) **Wollensak, G** and **Wollensak, J.** : Double contour of the lens capsule edges after continuous curvilinear capsulorhexis. *Graefes. Arch. Klin. Exp. Ophthalmol.* **235** : 204-207, 1997.
- 14) **Karp, C. L., Fazio, J. R., Culbertson, W. W.** and **Green, W. R.** : True exfoliation of the lens capsule. *Arch. Ophthalmol.* **117** : 1078-1080, 1999.
- 15) **Kuchle, M., Iliff, W. J.** and **Green, W. R.** : Combined true exfoliation and pseudoexfoliation of the anterior lens capsule. *Klin. Monatsbl. Augenheilkd.* **208** : 127-129, 1996.